



# Remodeling Process in the Right and Left Atria and Ventricles Following Percutaneous Closure of the Atrial Septal Defect in Children and Adolescents: A Mid-term Study

Hamid Amoozgar<sup>1</sup>, Saeed Safniyat<sup>2</sup>, Mohammad Reza Edraki<sup>3,\*</sup>, Hamid Mohammadi<sup>3</sup>, Nima Mehdizadegan<sup>1</sup>, Gholam Hossein Ajami<sup>3</sup>, Reza Dehghani<sup>4</sup>, Amir Naghshzan<sup>3</sup>, Neda Bagherian<sup>5</sup> and Sajad Shabanpuor-Haghighi<sup>5</sup>

<sup>1</sup>Neonatal Research Center, Shiraz University of Medical Sciences, Shiraz, Iran

<sup>2</sup>Pediatric Department, Shiraz University of Medical Sciences, Shiraz, Iran

<sup>3</sup>Cardiovascular Research Center, Shiraz University of Medical Sciences, Shiraz, Iran

<sup>4</sup>School of Medicine, Bam University, Bam, Iran

<sup>5</sup>School of Medicine, Jahrom University of Medical Sciences, Jahrom, Iran

\*Corresponding author: Cardiovascular Research Center, Shiraz University of Medical Sciences, Shiraz, Iran. Email: edrakidr@yahoo.com

Received 2020 December 26; Revised 2021 July 23; Accepted 2021 September 18.

## Abstract

**Background:** Atrial septal defect and its closure can lead to changes in the right and left cardiac cavities' function and size. In this study, Z-scores of the cardiac chambers and the heart function were assessed, and the important complications were mentioned.

**Methods:** This interventional cross-sectional study was done on patients who had atrial septal defect closure aged younger than 18 years. All patients were recruited for transthoracic echocardiography. About half of the patients were randomly selected. The information of angiography and its side effects belong to all patients, but the echocardiographic parameters and Z-scores belong only to the selected group.

**Results:** A total of 370 patients underwent the atrial septal defect closure, of whom 150 patients participated in the study. The patients' average age and weight were  $9.25 \pm 3.44$  years and  $15.12 \pm 11.83$  kg, respectively, and the mean follow-up time was 2.56 years. Z-scores of the interventricular septal dimension in diastole, the left ventricular posterior wall dimension in diastole, the left ventricular internal dimension in systole, and Z-scores of the size of the right atrium, right ventricle, pulmonary valve annulus, and the main pulmonary artery were more than Z-scores of the normal population. Furthermore, Z-scores of the E/A and the E<sub>at</sub>/A<sub>at</sub> of the tricuspid valve were less than their peers. Besides, the correlation between Z-scores and the atrial septal defect size and weight of the patients was assessed, which was statistically significant, and patients who underwent atrial special defect closure at the age of fewer than three years and less than 15 kg had more normal cardiac Z-scores.

**Conclusions:** Z-scores of the cardiac chambers and pulmonary artery were more than normal after successful closure of the atrial septal defect in the mid-term follow-up.

**Keywords:** Atrial Septal Defect, Cardiac Catheterization, Child, Z-Score

## 1. Background

Atrial special defect (ASD) can cause left-to-right shunt at the atrial level, right atrial and ventricular dilation (1, 2), arrhythmia, pulmonary vascular disease, and other complications, which in the long term, may lead to an increase in morbidity and negative heart function. Remodeling and changes in the heart function can happen following the closure of ASDs, which may be complete or incomplete (3, 4). Following ASD and its closure, the left ventricle changes will also be predictable according to the

ventricular-independent phenomenon (5-7). However, the changes in the right and left atria, ventricular size and function, and structural changes have not been fully identified following ASD closure (6). ASD closure may also have some complications, such as atrioventricular block, device displacement, aortic rupture, bleeding, and even death (1).

This study evaluated the cardiac cavities sizes and function by transthoracic echocardiography among children and adolescents whose ASDs were closed percutaneously, and the complications during the follow-up were specified.

## 2. Methods

Cardiac catheterization for the samples was done during 2010 - 2017 in Namazi teaching hospital of Shiraz University of Medical Sciences, Shiraz, Iran in this cross-sectional study. The patients were under the age of 18 years. Firstly, the previous echocardiography and angiographic records were checked out, and the characteristics regarding ASD size and the brand and size of the occluders and complications during angiography and follow-up were extracted from our database. The occluders were ASD with Amplatzer devices, and the average sizes of the used occluders were 20 - 25% bigger than the sizes of the ASDs in transthoracic echocardiography.

The inclusion criteria were QP/QS more than 1.5 in echocardiography and pulmonary vascular resistance less than 6 wood unit  $\times$  m<sup>2</sup> during the catheterization. The exclusion criteria were other interventions besides ASD closure, remaining shunts after ASD closure, other cardiac disorders, and cardiac arrhythmia before and after the procedures. Cardiac confounding factors were determined with echocardiography or cardiac catheterization, and pulmonary artery contrast injection with levophase was performed for all cases to rule out the abnormal pulmonary venous connection.

The patients were recruited for transthoracic echocardiography during 2018-2019, of whom half were selected randomly for echocardiography. In this study, both groups' information was provided, but the echocardiography characteristics belonged to the group accepted echocardiography. M-mode, 2-dimensional, flow Doppler, and tissue Doppler imaging (TDI) echocardiography was done for the selected group, and the function and dimensions of the right and left cardiac cavities, and the pulmonary artery and valve were evaluated (8).

Echocardiography was executed by the Samsung HS70A machine. The position of the patients was supine and left lateral during echocardiography. The echocardiographic data were determined as Z-score and divided into  $\leq -2$  and  $\geq 2$  Z-score groups. The Z-score parameters as the normal population with no ASD were obtained from the site: Nomograms for two-dimensional echocardiography derived valvular and arterial dimension in Caucasian children (9).

Size of the ASD and weight and age of the patients at the closure time are important factors during follow-up. Thus, we compared outcomes of the cardiac sizes and Z-scores of the patients with less and more than 15 mm ASD size, and less and more than 15 kg, and less and more than 3 years at the time of procedures.

Transthoracic echocardiography method: echocardiography was done on apical four chambers, subcostal, long axis, and short-axis views, and the sizes of the atria and ventricles and other cardiac parts were obtained according to the American Society of Echocardiography protocol (10).

In the parasternal long-axis view, the right atrium and ventricle dimensions in systole and diastole, interventricular septal thickness, and ejection fraction were assessed (Figure 1). In the four-chamber view, the cursor was placed on mitral and tricuspid valve leaflets, and the inflow E and A velocity, the dimension of the right atrium, and tricuspid annular plane systolic excursion (TAPSE) were recorded by the M-mode method.

Furthermore, in the four-chamber view, TDI was obtained while the cursor placed one cm apical to the mitral and tricuspid annuli, and pulse wave Doppler velocity was -20 to +20 cm/sec. An experienced pediatric cardiologist did echocardiography for all cases, and the parameters were obtained in three cycles, and the average values were used.

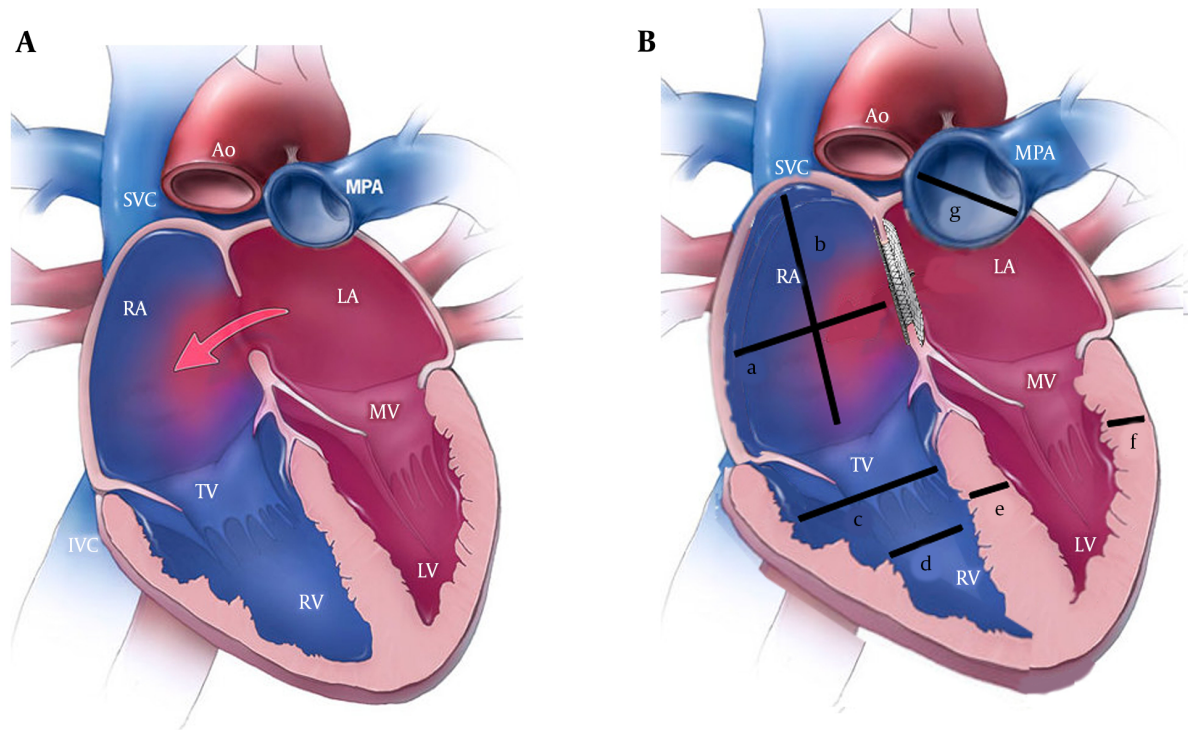
### 2.1. Statistical Analysis

The data were analyzed by SPSS version 23. The Kolmogorov-Smirnov test was used to assess the normal distribution, and continuous variables were described by mean  $\pm$  standard deviation and medium. The data were statistically analyzed by the Pearson's correlation test, *t*-test, and chi-squared test. The P-value < 0.05 was considered as the significance level.

## 3. Results

Totally, 370 patients underwent interventional ASD closure, of whom 150 cases, including 75 males and 75 females were selected for echocardiography. The patient's mean follow-up time was 2.56 years (range: 6 months to 6 years). The patient's demographic characteristics are presented in Table 1. The average size of the occluders was  $17.74 \pm 4.0$ . In 126 patients (84%), the device size was 12 - 23 mm, and in 24 patients, the device size was bigger than 24 mm. The brand names of the occluders were Occlutech (Figula) from Germany and Lifetech, Memopart, Cardiofix, Starway, and Comed from China.

The characteristics of M-mode echocardiography of the left ventricle, ejection fraction, and dimensions of the right atria and ventricles and the pulmonary artery are shown in Table 2. As it can be seen, 72% of these patients in the follow-up, in terms of interventricular septal dimension in diastole, had a Z-score of more than +2, and the left ventricular posterior wall dimension and the left ventricular internal dimension in systole of these patients were



**Figure 1.** (A) A schematic heart before atrial septal defect closure; (B) A schematic heart after atrial septal defect closure; a: Right atrial transverse dimension, b: Right atrial long axis dimension, c: Right ventricular end-diastolic diameter at the basal area; d: Right ventricular end-diastolic diameter at the mid cavity, e: Interventricular septal diameter in diastole, f: Left ventricular posterior wall diameter in diastole, and g: Main pulmonary artery. Abbreviations: ASD, atrial septal defect; TAPSE, tricuspid annular plane systolic excursion; TDI, tissue Doppler imaging.

**Table 1.** The Patients' Demographic Data and the Sizes of the Atrial Special Defects (ASDs) and Amplatzer

Characteristics	Mean $\pm$ SD
The patients' age at the time of catheterization (y)	3.3 $\pm$ 6.61
The patients' age at the time of the study (y)	9.25 $\pm$ 3.44
The patients' weight at the time of catheterization (y)	15.12 $\pm$ 11.83
The patients' weight at the time of the study (y)	13.06 $\pm$ 25.82
The size of atrial septal defects (mm)	14.43 $\pm$ 3.92
Device size (mm)	4.04 $\pm$ 17.74

significantly higher than their peers.

Although the right atria and ventricular dimensions were more than the same population, the TAPSE of this group was more than the same-age children and adolescents (Table 2). Therefore, the activity of the right ventricle was not reduced in this regard. According to Table 2, Z-scores of the pulmonary valve annulus and the main pulmonary artery at the follow-up time were higher than the normal population.

Besides, according to Tables 3 and 4, Z-scores of the flow

Doppler and TDI data of the mitral valve were not significantly different from the normal population, but the Z-scores of the E/A and E<sub>at</sub>/A<sub>at</sub> of the tricuspid valve in TDI was less than the peers. The tricuspid valve E-velocity was less than the peers, but the tricuspid valve A<sub>a</sub> velocity was similar to the normal population.

In terms of complications, 27 patients (7.29%) out of 370 patients had significant complications. One patient had femoral vein thrombosis (0.27), and in six patients, the occluders were displaced from the ASD site after releasing (1.62%). In three patients, the devices were embolized immediately after the device was released, and in three other patients, the devices were dislocated one, three, and seven days after implantation. Of these six patients, two patients' occluders were retrieved percutaneously, and the rest were removed in the operating room, and their ASDs were surgically closed. Furthermore, five out of 370 patients (1.35%), developed the third-degree atrioventricular block following device implantation and just before their release, and the devices were retrieved, and they were sent for surgery, and the heart block was resolved.

**Table 2.** M-Mode Echocardiographic Data of the Right Atrium and the Right and Left and Ventricles

Characteristics	Mean $\pm$ SD	Z-score $\pm$ SD	The Percentage of Patients with Z-scores $\geq 2$	The Percentage of Patients with Z-scores $\leq -2$
IVSDD (cm)	0.18 $\pm$ 0.708	1.88 $\pm$ 2.12	72	0
LVPWD (cm)	0.17 $\pm$ 0.72	1.50 $\pm$ 1.92	61	1
LVIDD (cm)	0.53 $\pm$ 3.66	1.20 $\pm$ 0.46	15	3
LVIDS (cm)	0.41 $\pm$ 2.15	1.59 $\pm$ 2.23	61	10
IVSS (cm)	0.25 $\pm$ 0.911	1.23 $\pm$ 0.63	9.3	1.3
LVPWS (cm)	0.21 $\pm$ 0.815	1.23 $\pm$ 0.96	2.6	18
EF%	9.58 $\pm$ 72.06	-	-	-
FS%	8.14 $\pm$ 41.10	-	-	-
TAPSE (cm)	2.21 $\pm$ 0.52	1.76 $\pm$ 0.81	55	2
Right atrial transverse dimension (cm)	3.24 $\pm$ 0.47	1.57 $\pm$ 0.78	40	4
Right atrial long axis dimension	3.57 $\pm$ 0.84	1.66 $\pm$ 0.93	45	0
RVED basal diameter (cm)	3.54 $\pm$ 12.58	1.89 $\pm$ 0.73	47	4
RVED mid cavity diameter	2.27 $\pm$ 8.22	1.74 $\pm$ 0.61	35	3
RVED length (cm)	5.61 $\pm$ 18.34	1.61 $\pm$ 0.95	33	2
Pulmonary annulus (cm)	1.99 $\pm$ 4.23	2.04 $\pm$ 1.21	68	0
Main pulmonary artery (cm)	2.11 $\pm$ 5.37	2.23 $\pm$ 1.19	70	0

Abbreviations: EF, ejection fraction; FS, fractional shortening; IVSDD, interventricular septal diameter at the end of diastole; IVSS, interventricular septal dimension in systole; LVIDD, left ventricular internal dimension in diastole; LVIDS, left ventricular internal dimension in systole; LVPWD, left ventricular posterior wall thickness in diastole; LVPWS, left ventricular posterior wall thickness in systole; RVEDD, right ventricular end-diastolic dimension; SD, standard deviation; TAPSE, tricuspid annular plane systolic excursion.

**Table 3.** Inflow Doppler Information of the Tricuspid and Mitral Valves

Characteristics	Mean $\pm$ SD	Z-score $\pm$ SD	The Percentage of the Patients with Z-scores $\geq 2$	The Percentage of the Patients with Z-scores $\leq -2$
Et	17.76 $\pm$ 75.81	-2.71 $\pm$ 0.71	0	57
At	16.10 $\pm$ 48.49	-0.85 $\pm$ 0.97	1	3.3
Et/At	1.33 $\pm$ 0.44	0.98 $\pm$ 0.63	2	48
Em	97.71 $\pm$ 25.12	1.21 $\pm$ 0.35	3	6
Am	55.08 $\pm$ 19.27	1.43 $\pm$ 0.51	2	3
Em/Am	1.99 $\pm$ 0.71	1.52 $\pm$ 0.61	4	6

Abbreviations: Am, peak A velocity in the mitral valve; AT, peak A velocity in the tricuspid valve; Em, peak E velocity in the mitral valve; Et, peak E velocity in the tricuspid valve; Em/Am, the ratio of peak E to peak A in the mitral valve; Et/At, the ratio of peak E to peak A in the tricuspid valve.

However, two out of 370 patients (0.59%) developed the third-degree atrioventricular block a few days after inserting the occluders. The ASD was closed surgically, but the heart block was not resolved, and for the second patient, a pacemaker was inserted into the heart without removing the Amplatzer.

Some chambers in ASDs larger than 15 mm were bigger at follow-up in comparison to the ASDs less than 15 mm, and there was a significant positive correlation among the right ventricular end-diastolic dimension at the basal part ( $r = 0.39$ ,  $P = 0.026$ ), the mid cavity part ( $r = 0.421$ ,  $P =$

0.031), pulmonary valve annulus ( $r = 0.33$ ,  $P = 0.042$ ) and the main pulmonary artery ( $r = 0.59$ ,  $P = 0.001$ ) in cases with larger ASDs. Besides, the flow Doppler velocity of the At was higher among the larger ones ( $r = 0.377$ ,  $P = 0.028$ ).

Also, Z-scores of some parameters were significantly higher in ASDs larger than 15 mm, in comparison to smaller than or equal to 15 mm so that the right atrial transverse dimensions were  $2.17 \pm 1.78$  and  $1.37 \pm 0.98$  ( $P = 0.045$ ), and the right ventricular end-diastolic dimensions at the basal part were  $2.16 \pm 0.83$  and  $1.33 \pm 0.65$  ( $P = 0.021$ ), the Z-scores of St were  $12.93 \pm 2.71$  and  $14.36 \pm 3.22$  ( $P = 0.034$ ), and the

**Table 4.** Tissue Doppler Information of the Tricuspid and Mitral Valves and the Interventricular Septum

Variables	Mean $\pm$ SD	Z-score $\pm$ SD	The Percentage of Patients with Z-scores $\geq 2$	The Percentage of the Patients with Z-scores $\leq -2$
Sat (cm/s)	2.81 $\pm$ 13.13	1.34 $\pm$ 0.20	9	5
Eat (cm/s)	3.56 $\pm$ 15.80	1.10 $\pm$ 0.31	2	2
Aat (cm/s)	3.74 $\pm$ 12.62	1.23 $\pm$ 0.79	19	0
Eat/Aat	4.99 $\pm$ 1.63	2.12 $\pm$ 0.75	0	43
Eas (cm/s)	3.37 $\pm$ 13.16	1.71 $\pm$ 0.25	11	3
Aas (cm/s)	2.76 $\pm$ 8.26	1.59 $\pm$ 1.31	22	0
Sam (cm/s)	8.61 $\pm$ 2.01	1.25 $\pm$ 1.24	11	5
Eam (cm/s)	13.65 $\pm$ 2.87	0.98 $\pm$ 0.78	9.24	4
Aam	5.53 $\pm$ 1.78	1.51 $\pm$ 1.13	10	11
Em/Aam	4.11 $\pm$ 1.25	1.34 $\pm$ 0.69	2	8

Abbreviations: Aam, mitral annular late diastolic velocity; Aas, septal annular late diastolic velocity; Aat, tricuspid annular late diastolic velocity; Eam, mitral annular early diastolic velocity; Eam/Aam, the ratio of early to late mitral annular diastolic velocity; Eas, septal annular early diastolic velocity; Eat, tricuspid annular early diastolic velocity; Eat/Aat, the ratio of early to late tricuspid annular diastolic velocity; SD, standard deviation; Sm, mitral annular systolic velocity; St, tricuspid annular systolic velocity.

Z-scores of At were  $4.67 \pm 1.33$  and  $5.70 \pm 2.30$  ( $P = 0.038$ ), respectively.

Furthermore, some parameters in patients less than or equal to 15 kg and above 15 kg had significant differences. In this regard, the Z-scores of the interventricular septal dimension in systole were  $0.32 \pm 0.10$  and  $0.72 \pm 0.12$  ( $P = 0.010$ ), and the Z-scores of the Et were  $-2.25 \pm 0.09$  and  $-2.8 \pm 0.06$  ( $P = 0.001$ ), respectively (Table 5).

In comparison to patients less than or equal to 3 years and older, the Z-scores of the Sat were  $0.19 \pm 0.21$  and  $-0.29 \pm 0.13$ , ( $P = 0.49$ ), Z-scores of the Aat were ( $1.14 \pm 0.15$  and  $0.67 \pm 0.13$  ( $P = 0.042$ ), Z-scores of the Aas were ( $1.80 \pm 0.28$  and  $1.11 \pm 0.15$  ( $P = 0.020$ ), and Z-scores of the At were ( $-0.39 \pm 0.25$  and  $-1.04 \pm 0.11$  ( $P = 0.009$ ) respectively, and there were significant statistically differences; however, they were in the normal range (Table 6).

Furthermore, out of 370 patients, three cases (0.81%) had congenital third-degree heart block with appropriate heart rate before ASD closure, and positive anti-Ro/SSA antibody in the mother, but following ASD closure, they experienced a decrease in the heart rate that permanent pacemaker was inserted for them.

#### 4. Discussion

The presence of ASD, if there is an indication of closure, can lead to the enlargement of the right atrium and ventricle and reduces the dimensions of the left atrium and ventricle. Also, the ASD closure can move the dimensions of the cavities and parts of the heart toward normal (11).

In some studies, echocardiographic parameters have been studied by two interventional and surgical methods. After the mid-term follow-up, echocardiographic data had less diversion from the normal population in the intervention method than the surgical method (12, 13). However, there was no difference between surgical and interventional methods in most studies according to the outcome (14-17). Some studies have shown that ASD closure reduces the size of the right anatomical structures and increases the left side of the heart (18).

Blood flow and TDI data of patients were also examined and compared to normal cases by researchers. Although no study or few has been done on the Z-scores of the cardiac cavities and the main pulmonary artery and the echocardiographic parameters after ASD closure, the parameters mentioned above were assessed in this study.

In some studies, following the closure of ASDs, the left ventricular ejection fraction increased, whereas the TAPSE decreased. It seems that further blood flow to the left side of the heart can increase the size of the left cardiac chambers, and also, along with an increase in the left ventricular preload, the ejection fraction increases according to Frank Sterling's law (19). Furthermore, after reducing the preload of the right cardiac chambers, the size of these cavities and the TAPSE will reduce. Nonetheless, in some studies, the mitral annular plane systolic excursion showed an increase, but the TAPSE did not (20).

However, a remarkable percentage of the patients had a Z-score  $> 2$  after 2.5 years of follow-up regarding the right cardiac sizes, and the diameter of the pulmonary valve annulus, pulmonary artery diameter, TAPSE, the interventric-

**Table 5.** Comparison of the Variables at the Follow-up According to the Weight of the Patients at the Time of Intervention <sup>a</sup>

Variables	Group		P-Value
	≤ 15 kg	> 15 kg	
EF%	72.92 ± 1.79	72.05 ± 0.89	0.655
FS%	41.61 ± 1.69	41.29 ± 0.78	0.852
Z-score -IVSD	1.72 ± 0.23	2.27 ± 0.19	0.141
Z-score -LVIDD	0.35 ± 0.21	0.50 ± 0.11	0.537
Z-score -LVIDS	-0.45 ± 0.19	-0.20 ± 0.17	0.458
Z-score -IVPWD	2.08 ± 0.29	1.86 ± 0.13	0.473
Z-score -LVPWS	-1.15 ± 0.25	-0.90 ± 0.11	0.323
Z-score -IVSS	0.32 ± 0.10	0.72 ± 0.12	0.010
Z-score -Sat	0.07 ± 0.27	-0.22 ± 0.12	0.281
Z-score -Eat	-0.35 ± 0.17	-0.27 ± 0.10	0.704
Z-score -Aat	0.85 ± 0.19	0.80 ± 0.12	0.827
Z-score -Sas	0.53 ± 0.25	0.37 ± 0.16	0.613
Z-score -Eas	-0.29 ± 0.24	0.12 ± 0.17	0.227
Z-score -Aas	1.32 ± 0.31	1.31 ± 0.15	0.971
Z-score -Et	-2.25 ± 0.09	-2.84 ± 0.06	0.001
Z-score -At	-0.74 ± 0.17	0.89 ± 0.14	0.576
Z-score -TAPSE (cm)	1.21 ± 0.52	1.36 ± 0.81	0.651
Z-score -right atrial transverse dimension (cm)	1.61 ± 0.39	1.57 ± 0.69	0.257
Z-score -right atrial long axis dimension (cm)	1.19 ± 0.72	1.71 ± 0.72	0.549
Z-score -RVEDwidth in the basal area (cm)	1.54 ± 1.49	1.28 ± 0.53	0.813
Z-score -RVED width in the mid-cavity (cm)	1.22 ± 1.49	1.34 ± 0.61	0.122
Z-score -RVED length (cm)	1.62 ± 1.38	1.47 ± 0.78	0.425

Abbreviations: Aas, septal tissue late diastolic velocity; Aat, tricuspid annular late diastolic velocity; At, peak A velocity in the tricuspid valve; Eas, septal tissue early diastolic velocity; Eat, tricuspid annular early diastolic velocity; EF, ejection fraction; Et, peak E velocity in the tricuspid valve; FS, fractional shortening; IVSD, interventricular septal thickness in diastole; IVSS, interventricular septal thickness in systole; LVIDD, left ventricular internal dimension in diastole; LVIDS, left ventricular dimension in systole; LVPWD, left ventricular posterior wall thickness in diastole; LVPWS, left ventricular posterior wall thickness in systole; RVED, right ventricular end-diastolic dimension; Sas, septal tissue systolic velocity; Sat, tricuspid annular systolic velocity; TAPSE, tricuspid annular plane systolic excursion.

<sup>a</sup>Values are expressed as mean ± SD.

ular septal dimension in diastole, left ventricular posterior wall dimension in diastole, and the left ventricular internal dimension in systole.

On the other hand, in some studies, in patients with ASD, apical right ventricular strain parameters were higher than the basal part, and after the ASD closure, the strain of both parts reduced (1). In another study, patients before and after ASD closure were examined for blood flow Doppler echocardiography and TDI, in which the Et/At decreased and Et/et increased, but there was no diversion in TDI parameters (21, 22). In our study, a Z-score ≤ 2 was observed in the Et/At and Eat in a noticeable percentage of subjects after ASD closure (Tables 4 and 3).

In a study, in the adult cases, echocardiographic results of ASD closure before and after 25 years old were compared

to older cases, and tricuspid regurgitation increased significantly more than the other group (23).

In our study, if the age at the ASD closure was three years old, Z-scores of the Sat, Aat, Aas, and At were significantly lower than the age of over three years. Also, regarding the correlation between ASD size greater than and smaller than 15 mm, the Z-scores of the right cardiac chamber sizes, the pulmonary valve annulus, and the main pulmonary artery were higher in patients with the larger ASDs.

Our study compared ASD closure among patients under and more than 15 kg and showed that those with lower weight had lesser interventricular septal dimension in systole.

According to our study, closure of the large ASDs might



**Table 6** . Comparison of the Variables at the Follow-up According to the Age Classification at the Time of Intervention <sup>a</sup>

Variables	Group		P-Value
	≤ 3 (y)	> 3 (y)	
EF%	70.99 ± 11.60	72.73 ± 0.86	0.38
FS%	40.76 ± 1.72	41.59 ± 0.72	0.65
Z-score-IVSD	2.12 ± 0.26	2.16 ± 0.19	0.91
Z-score-IVIDD	0.22 ± 0.19	0.57 ± 0.11	0.11
Z-score-IVIDS	-0.27 ± 0.34	-0.25 ± 0.13	0.97
Z-score-IVPWD	1.83 ± 0.23	1.94 ± 0.15	0.69
Z-score-IVPWS	-1.01 ± 0.17	-0.93 ± 0.12	0.73
Z-score-IVSS	0.42 ± 0.21	0.71 ± 0.11	0.20
Z-score-Sat	0.19 ± 1.33	-0.29 ± 1.33	0.049
Z-score-Eat	-0.28 ± 0.17	-0.29 ± 1.11	0.93
Z-score-Aat	1.14 ± 0.15	0.67 ± 0.13	0.42
Z-score-Sas	0.74 ± 0.34	0.28 ± 0.13	0.12
Z-score-Eas	-0.69 ± 0.18	0.31 ± 0.18	0.000
Z-score-Aas	1.80 ± 0.28	1.11 ± 0.15	0.02
Z-score-Et	-2.60 ± 0.12	-2.7 ± 0.62	0.28
Z-score-At	-0.39 ± 0.25	-1.04 ± 0.11	0.009
Z-score-TAPSE (cm)	1.21 ± 0.52	1.36 ± 0.81	0.651
Z-score-right atrial transverse dimension (cm)	1.82 ± 0.39	1.45 ± 0.69	0.341
Z-score-right atrial long axis dimension (cm)	1.76 ± 0.61	1.74 ± 0.49	0.649
Z-score-RVED width in the basal area (cm)	1.54 ± 0.99	1.28 ± 0.75	0.568
Z-score-RVED width in the mid-cavity (cm)	1.92 ± 1.63	1.92 ± 0.78	0.922
Z-score-RVED length (cm)	1.71 ± 0.99	1.83 ± 0.86	0.701

Abbreviations: Aas, septal tissue late diastolic velocity; Aat, tricuspid annular late diastolic velocity; At, peak A velocity in the tricuspid valve; Eas, septal tissue early diastolic velocity; Eat, tricuspid annular early diastolic velocity; EF, ejection fraction; Et, peak E velocity in the tricuspid valve; FS, fractional shortening; IVSD, interventricular septal thickness in diastole; IVSS, interventricular septal thickness in systole; IVIDD, left ventricular internal dimension in diastole; IVIDS, left ventricular dimension in systole; LVPWD, left ventricular posterior wall thickness in diastole; LVPWS, left ventricular posterior wall thickness in systole; RVED, right ventricular end-diastolic dimension; Sas, septal tissue systolic velocity; Sat, tricuspid annular systolic velocity; TAPSE, tricuspid annular plane systolic excursion.

<sup>a</sup>Values are expressed as mean ± SD.

be recommended earlier, at the age of fewer than three years and the weight of less than 15 kg, to prevent dilating the right cardiac chambers; however, this suggestion should be further examined in the next studies.

Furthermore, the third-degree heart block can occur in some patients, and several studies have declared that this impediment can be treated with steroids (17). However, in one of our patients, steroids could not solve the problem, and the Amplatzer was removed surgically after two weeks, and the ASD was closed with surgical method, and the cardiac block remained. In our second patient, following the block, the steroid was prescribed, but the block did not resolve, and a pacemaker was used. Nonetheless, some studies have suggested that the block may be resolved by steroids administration, and the block of some patients

has been removed through the retrieval of the Amplatzer (24).

#### 4.1. Conclusions

The larger ASDs possibly have more adverse effects on the Z-scores than the smaller ones after closure, and the larger ASDs should be closed earlier.

Patients who underwent ASD closure at the age of fewer than three years had more normal cardiac Z-scores than cases over three years, and longer follow-ups require to find out the adverse effects of the ASD on the cardiac Z-scores.

## Acknowledgments

We appreciate the Shiraz University of Medical Sciences for its non-financial supports.

## Footnotes

**Authors' Contribution:** HA: Conception, design, and final approval; SS: Statistical management; ME: Conception, design, and statistical management; HM: Conception; NM: Revisions of the manuscript; GA: Echocardiography; RD: English edition; AN: design; NB: Conception; SSH: Statistical management. All authors read and approved the final manuscript.

**Conflict of Interests:** None declared, and the authors did not receive any direct or indirect financial payment for the research and are not owners of any related company and are not consultants of these companies.

**Data Reproducibility:** Concerning data availability, we state that the data used and/or analyzed during the current study are available from the corresponding author on reasonable request.

**Ethical Approval:** This study was approved by the Ethics Committees of Shiraz University of Medical Sciences (ethical code: IR.SUMS.med.rec 1395-01-01 13459). All procedures were conducted according to the ethical standards of the relevant national guidelines on human experimentation of institutional and ethics committees. Furthermore, the study was according to the Helsinki Declaration of 1975 and its revised version in 2008. For all parents or guardians, the topic and methods were explained, and written consent was taken.

**Funding/Support:** There was no funder for this research.

**Informed Consent:** This manuscript does not contain any personal data, and the consent for publication is applicable, and the patient guardians gave us the consent for these clinical and image data to be published in this study.

## References

1. Van De Bruaene A, Buys R, Vanhees L, Delcroix M, Voigt JU, Budts W. Regional right ventricular deformation in patients with open and closed atrial septal defect. *Eur J Echocardiogr*. 2010;**12**(3):206-13. doi: [10.1093/ejehocardiography/jeq169](#).
2. Moons P, Sluysmans T, De Wolf D, Massin M, Suys B, Benatar A, et al. Congenital heart disease in 111 225 births in Belgium: birth prevalence, treatment and survival in the 21st century. *Acta Paediatr*. 2009;**98**(3):472-7. doi: [10.1111/j.1651-2227.2008.01152.x](#). [PubMed: [19046347](#)].
3. Swan L, Varma C, Yip J, Warr M, Webb G, Benson L, et al. Transcatheter device closure of atrial septal defects in the elderly: technical considerations and short-term outcomes. *Int J Cardiol*. 2006;**107**(2):207-10. doi: [10.1016/j.ijcard.2005.03.027](#). [PubMed: [16412798](#)].
4. Ackermann S, Quandt D, Hagenbuch N, Niesse O, Christmann M, Knirsch W, et al. Transcatheter atrial septal defect closure in children with and without fluoroscopy: A comparison. *J Interv Cardiol*. 2019;**2019**:6598637. doi: [10.1155/2019/6598637](#). [PubMed: [31772540](#)]. [PubMed Central: [PMC6739773](#)].
5. Walker RE, Moran AM, Gauvreau K, Colan SD. Evidence of adverse ventricular interdependence in patients with atrial septal defects. *Am J Cardiol*. 2004;**93**(11):1374-7. A6. doi: [10.1016/j.amjcard.2004.02.033](#). [PubMed: [15165917](#)].
6. Balci KG, Balci MM, Aksoy MM, Yilmaz S, Ayturk M, Dogan M, et al. Remodeling process in right and left ventricle after percutaneous atrial septal defect closure in adult patients. *Turk Kardiyol Dern Ars*. 2015;**43**(3):250-8. doi: [10.5543/tkda.2015.57106](#). [PubMed: [25905996](#)].
7. Schiller NB, Shah PM, Crawford M, DeMaria A, Devereux R, Feigenbaum H, et al. Recommendations for quantitation of the Left ventricle by two-dimensional echocardiography. *J Am Soc Echocardiogr*. 1989;**2**(5):358-67. doi: [10.1016/S0894-7317\(89\)80014-8](#).
8. Ajami G, Edraki MR, Moarref AR, Amirghofran AA, Borzouee M, Amoozgar H, et al. Role of speckle tracking echocardiography in the assessment of post-repair left ventricular function in patients with late presentation of anomalous origin of the left coronary artery from the pulmonary artery. *Cardiol Young*. 2015;**25**(5):969-75. doi: [10.1017/S1047951114001486](#). [PubMed: [25155805](#)].
9. Cantinotti M, Giordano R, Scalese M, Murzi B, Assanta N, Spadoni I, et al. Nomograms for two-dimensional echocardiography derived valvular and arterial dimensions in Caucasian children. *J Cardiol*. 2017;**69**(1):208-15. doi: [10.1016/j.jcc.2016.03.010](#).
10. Gottdiener JS, Bednarz J, Devereux R, Gardin J, Klein A, Manning WJ, et al. American Society of Echocardiography recommendations for use of echocardiography in clinical trials: A report from the american society of echocardiography's guidelines and standards committee and the task force on echocardiography in clinical trials. *J Am Soc Echocardiogr*. 2004;**17**(10):1086-119. doi: [10.1016/j.echo.2004.07.013](#). [PubMed: [15452478](#)].
11. Foo JS, Lazu M, Pang SY, Lee PT, Tan JL. Comparative analysis of right heart chamber remodeling after surgical and device secundum atrial septal defect closure in adults. *J Interv Cardiol*. 2018;**31**(5):672-8. doi: [10.1111/joic.12528](#). [PubMed: [29869426](#)].
12. Agac MT, Akyuz AR, Acar Z, Akdemir R, Korkmaz L, Kiriş A, et al. Evaluation of right ventricular function in early period following transcatheter closure of atrial septal defect. *Echocardiography*. 2012;**29**(3):358-62. doi: [10.1111/j.1540-8175.2011.01558.x](#). [PubMed: [22066780](#)].
13. Kumar P, Sarkar A, Kar SK. Assessment of ventricular function in patients of atrial septal defect by strain imaging before and after correction. *Ann Card Anaesth*. 2019;**22**(1):41-6. doi: [10.4103/aca.ACA\\_153\\_17](#). [PubMed: [30648678](#)]. [PubMed Central: [PMC6350442](#)].
14. Kim JY, Yun BS, Lee S, Jung SY, Choi JY, Kim NK. Changes in strain pattern and exercise capacity after transcatheter closure of atrial septal defects. *Korean Circ J*. 2017;**47**(2):245-53. doi: [10.4070/kcj.2016.0205](#). [PubMed: [28382081](#)]. [PubMed Central: [PMC5378032](#)].
15. Kubota S, Hoashi T, Kagisaki K, Yazaki S, Kobayashi J, Shiraishi I, et al. The outcomes of surgical ASD closure in the era of catheter ASD closure; experience of single institute. *J Cardiothorac Surg*. 2013;**8**(S1). doi: [10.1186/1749-8090-8-s1-p141](#).
16. Ooi YK, Kelleman M, Ehrlich A, Glanville M, Porter A, Kim D, et al. Transcatheter versus surgical closure of atrial septal defects in children: A value comparison. *JACC Cardiovasc Interv*. 2016;**9**(1):79-86. doi: [10.1016/j.jcin.2015.09.028](#). [PubMed: [26762915](#)].



17. Tomar M, Khatri S, Radhakrishnan S, Shrivastava S. Intermediate and long-term followup of percutaneous device closure of fossa ovalis atrial septal defect by the Amplatzer septal occluder in a cohort of 529 patients. *Ann Pediatr Cardiol.* 2011;**4**(1):22–7. doi: [10.4103/0974-2069.79618](https://doi.org/10.4103/0974-2069.79618). [PubMed: [21677800](https://pubmed.ncbi.nlm.nih.gov/21677800/)]. [PubMed Central: [PMC3104526](https://pubmed.ncbi.nlm.nih.gov/PMC3104526/)].
18. Pourarian S, Rezaie M, Amoozgar H, Shakiba AM, Edraki MR, Mehdizadegan N. High-dose oral ibuprofen in treatment of patent ductus arteriosus in full-term neonates. *Iran J Pediatr.* 2015;**25**(4). e2005. doi: [10.5812/ijp.2005](https://doi.org/10.5812/ijp.2005). [PubMed: [26396694](https://pubmed.ncbi.nlm.nih.gov/26396694/)]. [PubMed Central: [PMC4575792](https://pubmed.ncbi.nlm.nih.gov/PMC4575792/)].
19. Chen Q, Sun XD, Cao H, Zhang GC, Chen LW, Hu YN. Echocardiographic evaluation of changes in cardiac hemodynamics and loading conditions after transthoracic minimally invasive device closure of atrial septal defect. *PLoS One.* 2015;**10**(7). e0128475. doi: [10.1371/journal.pone.0128475](https://doi.org/10.1371/journal.pone.0128475). [PubMed: [26147594](https://pubmed.ncbi.nlm.nih.gov/26147594/)]. [PubMed Central: [PMC4493115](https://pubmed.ncbi.nlm.nih.gov/PMC4493115/)].
20. Kort HW, Balzer DT, Johnson MC. Resolution of right heart enlargement after closure of secundum atrial septal defect with transcatheter technique. *J Am Coll Cardiol.* 2001;**38**(5):1528–32. doi: [10.1016/s0735-1097\(01\)01547-9](https://doi.org/10.1016/s0735-1097(01)01547-9).
21. Akula VS, Durgaprasad R, Velam V, Kasala L, Rodda M, Erathi HV. Right ventricle before and after atrial septal defect device closure. *Echocardiography.* 2016;**33**(9):1381–8. doi: [10.1111/echo.13250](https://doi.org/10.1111/echo.13250). [PubMed: [27109837](https://pubmed.ncbi.nlm.nih.gov/27109837/)].
22. Shojaeifard M, Moradian M, Daneshamooz H, Ghadrdoost B, Langeroudi H, Khorgami M. Echocardiographic right ventricular deformation indices before and after atrial septal defect closure: A comparison between device and surgical closure. *Res Cardiovasc Med.* 2018;**7**(2). doi: [10.4103/rcm.rcm\\_5\\_18](https://doi.org/10.4103/rcm.rcm_5_18).
23. Oliver JM, González AE, Benito F, Sanz E, Aroca Á, Mesa JM, et al. Surgical closure of atrial septal defect before or after 25 years of age. Comparison with the natural history in non-operated patients (English Edition). *Revista Española de Cardiología.* 2002;**55**(9):953–61. doi: [10.1016/s0300-8932\(02\)76734-1](https://doi.org/10.1016/s0300-8932(02)76734-1).
24. Williams D, Welch A, Ootaki Y. Early progressive atrioventricular block after amplatzer septal occluder closure of a large atrial septal defect. *Ann Case Rep Imaes.* 2019;**2**(1). doi: [10.24983/scitemed.acri.2019.00118](https://doi.org/10.24983/scitemed.acri.2019.00118).